

# The RIGHT START for the big boy in your life!



## PUPPY – LARGE BREED FORMULA

REAL CHICKEN IS THE #1 INGREDIENT

Purina PRO PLAN Puppy Large Breed Formula has been scientifically formulated to meet the dietary requirements of puppies weighing over 22.5kg at maturity to give him the best start to his life.

- **NATURAL SOURCES OF GLUCOSAMINE** to help support joint health and mobility by supplying building blocks for the generation of cartilage
- **AN OPTIMAL PROTEIN: FAT RATIO** helps your puppy maintain lean muscle mass and a healthy body condition when fed appropriately
- **APPROPRIATE LEVELS OF FAT AND CALORIES** to help maintain ideal body condition
- **CONTAINS DHA** a nutrient found in mother's milk for brain and vision development

We carefully select each and every ingredient for its nutritional value and to ensure it meets our strict quality standards. That's why you can be sure that your Large Breed puppy receives exceptional nutrition and flavour in every bowl. **GUARANTEED.**



Veterinary Specialist Group

# The Next Step

Issue 6, October 2006

EXPERTISE • TECHNOLOGY • COMPASSION

## Dr Mike Coleman; A "Home-Grown" Internal Medicine Specialist

The whole team at Veterinary Specialist Group would like to recognize the achievement of Dr Mike Coleman in becoming a Fellow of the Australian College of Veterinary Scientists (ACVSc) and a Registered Specialist in Small Animal Internal Medicine. The program of case-work, study, research and publications that makes up the requirements for Fellowship is as rigorous as any in the world, and in some aspects more onerous. For instance, Mike has published five first-author papers (including an original research report) in peer-reviewed journals, a fantastic achievement. Mike is one of the easiest guys to get on with that you can possibly imagine, and is a very calm influence around the sometimes hectic corridors at VSG. He is simply unflappable! He now has the most current knowledge of any Internist in the country and his clinical skills are world class.

At VSG we have recognised that growth and expansion of services takes the time and energy of many Specialists, and in a world that is hungry for the services of Internists it is crucial that we are able to generate our own home-grown clinicians. To our knowledge Mike is the first Specialist in Internal Medicine to be trained in New Zealand

and is one of the very few in Australasia to have come out of a private practice environment rather than a university program. Mike has already volunteered for service on the Fellowship exam committee, where he looks forward to making the lives of prospective candidates just as difficult as his has



been for the last year (joke!) and has plans for new services at VSG, especially in his field of special interest; cardiology. We have an ongoing Residency program in Internal Medicine at VSG, the latest incumbent is Dr Danielle Bowles and we hope to have a rolling schedule of Residents with a new candidate starting each year as in similar programs in the USA.

All of us at VSG would also like to congratulate the other New Zealanders who have achieved Fellowship status this year; Dr Andrew Worth (Small Animal Surgery) and Dr Mark Owen (Diagnostic Imaging) from Massey and Dr Helen Milner (Small Animal Surgery) from VetSpecs in Christchurch.

## VSG Launches New Website

We have recently launched a new website which provides a variety of information for referring veterinarians and clients. A full staff listing is complemented by a list of the services available within each department at VSG. Information sheets for various conditions for both veterinarians and clients are available for download, along with our brochure, and previous copies

of "The Next Step" newsletter. A step by step list of the referral process is available for veterinarians, along with case notes from VSG of previous cases of interest. A patient photo gallery shows some of the patients who have been to VSG.


Check out the website at [www.vsg.co.nz](http://www.vsg.co.nz)



*This edition of The Next Step is centred around one patient, Tai the Huntaway from Northland. The sequence of events that led to his referral to VSG and management by multiple veterinary specialists and nurses epitomizes the team approach that we practice here. A concerned owner, an enthusiastic primary veterinarian and a fast-moving multi-disciplinary approach (together with some luck!) achieved a great outcome for a dog that came very close to dying several times during the process. We will use Tai's story as a springboard for discussions of managing sepsis, obtaining good splenic radiographs and performing a safe splenectomy. Tai's owner and primary veterinarian give their sides of the story for a different perspective as well.*

## Strong Ties Make the Difference - by Jane Finlayson, Backbone Marketing Ltd

Tai Thomson is munching mutton on the lawn after a good day's work and he barks in response to a whistle from inside the house. Tai is a 6 year old Huntaway who earns his keep working and dog trialling with his owner Guy Thomson. Back in June this well-bred and trained dog was on the brink of death with no apparent cause.



Guy Thomson is one of those rural New Zealand gems - hard working, community minded and passionate about his dogs. The retired farmer, in his late 70s, lives on 14 acres just outside of Kaikohe in Northland with his best mate Tai and Wee Wee, a mouse-hunting Jack Russell. As well as working on local properties Guy is an active and successful dog triallist at both a local and national

level. He has had a number of strong Huntaways including Tai's sire Cruz who was highly placed in the Nationals in 2002. Guy rates Tai as every bit as good as his father so when Tai "got a bit crook" he was concerned.

It was only a month after he and Tai had competed at the national dog trials at Omarama in May this year when things started to go wrong. "We had been working with cattle Tb testing on the Tuesday and by the Friday when we were



having the tests read I noticed Tai was dragging the anchor. We came home for lunch and by 2pm he had disappeared and didn't respond to my whistle - I found him in the bamboo hedge and knew things were bad." At this point Guy quickly got Tai to Bay of Island Vets, Kaikohe branch where Jenni Petersen examined him.


Jenni says "Tai presented with acute abdominal pain and on testing seemed to have haemoglobin everywhere. We hospitalised Tai and placed him on a drip and used plasma." By the end of the weekend the team at BOI were still without a diagnosis and Tai was not doing well.

"At this point Guy had asked us to put him down because he did not want his mate to suffer. I discussed referral with Guy and he initially said no, but I knew how much Tai meant to him. So I rang VSG who said as an important step they needed to perform an ultrasound."

It was here that Jenni's relationship with Guy proved to be a critical factor for Tai. Guy explains "I've known Jenni all her life and was happy to back her judgement so when she came back to me and wanted me to let the experts take a look at Tai I agreed. It was her day off the next day and she took us all the way to VSG in Auckland - she was mighty!"

When Chris Warman conducted the ultrasound he discovered a twisted spleen and following a consultation and agreement from everyone, Richard Jerram performed emergency surgery. Tai's survival was still very much in the balance and his post operative intensive care and recovery was managed by Mike Coleman and the medical team.

After the surgery Guy went home



and waited, "Jenni kept in constant touch with VSG and me, and it was Saturday before we got our first positive report on Tai's recovery."

By the Monday Tai had managed to walk out to the waiting area to see Guy. "I was pretty pleased to see him." On the Wednesday, after 8 days of intensive care and treatment Tai got to go home.

Richard Jerram recalls "When we opened him up it was not pretty - the spleen had been twisted for some time and it didn't smell good - initially I didn't rate Tai's chances highly but we did everything that we could for him. It was one of those cases that had every one in the VSG team involved so we were all delighted to see Tai go home with Guy. They had a special bond."

Jenni says that this was the first time she had referred a patient to VSG and was really impressed. "VSG were fantastic - the client is really happy with the outcome and Tai is looking great. I'd definitely use them again where the client and situation was appropriate."

Guy says it cost him over \$6000 to get Tai back to where he was. "My magnificent mate is a ball of muscle again and back working. We will be aiming to qualify for the Nationals again in 2007 - I wouldn't have that chance if I had had to start with a new dog - so it was money well spent - thanks to Jenni and everyone at VSG who really went the extra mile."



## Contacts



**DR. ALEX WALKER** Specialist in Small Animal Surgery  
surgery@vsg.co.nz



**DR. CHRIS WARMAN** Specialist in Veterinary Radiology  
radiology@vsg.co.nz



**DR. MARK ROBSON** Specialist in Small Animal Medicine  
medicine@vsg.co.nz



**DR. RICHARD JERRAM** Specialist in Small Animal Surgery  
surgeryrj@vsg.co.nz



**DR. DARREN FRY** Specialist in Small Animal Medicine  
d.fry@vsg.co.nz



**DR. MIKE COLEMAN** Specialist in Small Animal Medicine  
m.coleman@vsg.co.nz



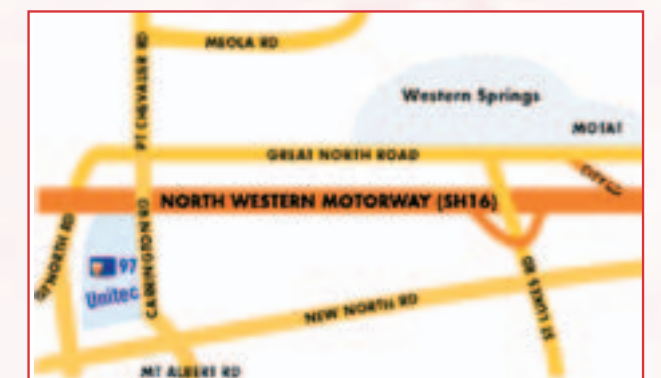**DR. DANIELLE BOWLES** Small Animal Medicine Resident  
d.bowles@vsg.co.nz

97 Carrington Road Mt Albert Auckland

Phone: (09) 845 5455. Fax: (09) 845 5456

Email: office@vsg.co.nz Website: www.vsg.co.nz

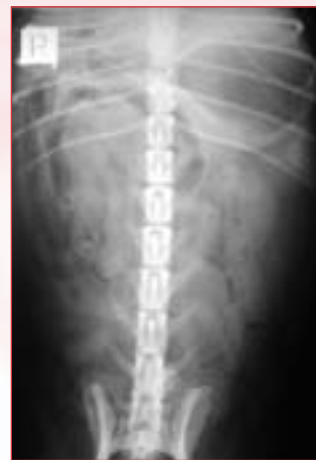The Veterinary Specialist Group hospital is located on the Unitec campus situated between Gates 2 and 3 on Carrington Road.



## Splenic Imaging – by Chris Warman

Diagnostic imaging of the spleen becomes of interest when a patient presents with abdominal distention, a palpable abdominal mass, anomalies of the red blood cell series, a cardiac arrhythmia without apparent primary cardiac structural pathology and as part of tumor staging. Ultrasound and radiology are the imaging modalities most commonly utilized to evaluate the spleen in veterinary medicine.

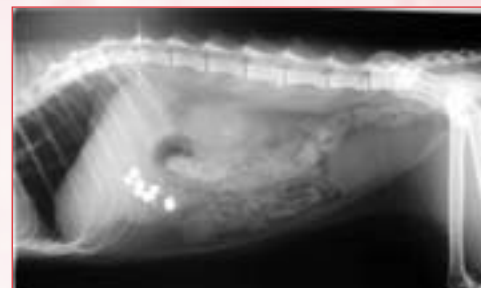
Ultrasound is far more informative than radiology in the assessment of splenic anatomy and pathology. Ultrasound allows the clinician to evaluate size, shape, location, splenic parenchymal sonographic architecture and vascular supply with ease. Ultrasound is sensitive to subtle changes in splenic parenchymal



**Figure 1**  
A triangular soft tissue radiopacity in the cranial left quadrant on the ventrodorsal image is the typical finding in a normal cat and dog.

architecture and readily detects small mass lesions that would not be apparent on survey radiographs. The splenic vasculature can also be readily evaluated without the need to resort to contrast studies. Ultrasound also has the distinct advantage of being able to evaluate abdominal structures, including the spleen, in the face of severe peritoneal effusion. The loss of serosal detail as a result of free abdominal fluid limits the diagnostic value of radiology when peritoneal effusion is present. Radiology however can be of significant diagnostic value so long as the clinician is aware of the limitations of this imaging modality. In order to accurately radiographically evaluate the spleen, it is important to recognize certain key points.

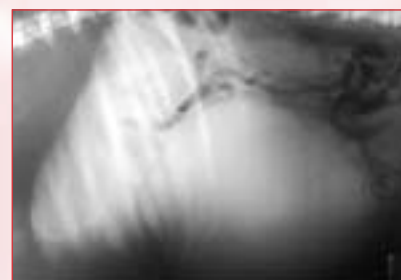- The head of the spleen (dorsal aspect) is relatively immobile, fixed by the gastrosplenic ligament to the greater curvature of the stomach.
- The body and tail of the spleen are very mobile and are easily displaced. This mobility of the body and tail ultimately means the location of the spleen and shape of the spleen can be extremely variable on abdominal radiographs of the canine patient.



**Figure 2**  
The right recumbent lateral image of a feline patient failing to reveal a splenic shadow dorsal to the ventral abdominal wall.

- The spleen reveals a relatively stable shape and location in two areas in the normal canine patient. In the ventrodorsal view of the abdomen the spleen is identified as a triangular, radiopaque structure relative to the surrounding abdominal fat, lying lateral or caudal-lateral to the gastric fundus. In the right recumbent lateral radiograph the body and tail of the spleen also reveals a triangular shaped pattern immediately dorsal to the ventral abdominal wall. The position of the spleen in lateral recumbency is dependent upon hepatic size and gastric distention. The more caudally displaced the spleen becomes in this position the larger it appears. The increase in size is largely a feature of object-film distance distortion. In the left recumbent lateral radiograph the spleen is frequently difficult to identify and may not reveal the typical triangular shape identified in the right dependent lateral radiograph. In the left recumbent lateral radiograph, particularly if the spleen is small, the spleen summates with intestinal structures and identification of the spleen can be somewhat challenging. In the left recumbent lateral radiograph the spleen needs to cross the left midline of the abdomen to be readily identified.

- A mass effect within the spleen results in displacement of local abdominal structures. A mass effect within the head of the spleen will result in caudal displacement of the left kidney and small bowel displacement both caudally and to the right in the ventrodorsal view.



**Figure 3**  
A large mid abdominal mass, resulting in significant intestinal displacement in a canine patient. The mass can be considered almost certainly splenic in origin.

A mass within the head of the spleen will result in ventral displacement of the colon and ventral-caudal displacement of small bowel in the lateral radiograph. A mass lesion within the tail of the spleen may result in medial displacement of the proximal duodenum and ascending colon in the ventrodorsal view. Similar displacement may occur with generalized splenomegaly. A mass effect in the body and the tail of the spleen will result in caudal and dorsal displacement of the small bowel on lateral radiographs.

- The most common cause of a mid abdominal mass in canine patients is a splenic lesion.
- The feline patient reveals less variability in splenic shape and positioning.
- The spleen is frequently difficult to identify in lateral radiographs of the cat abdomen unless it is enlarged.
- The spleen is best identified in the feline patient in the ventrodorsal image. The spleen in the cat, as with the dog, is identified as a triangular radiopacity in the left cranial abdomen adjacent the gastric fundus.

## Medical Management of the Septic Patient – by Michael Coleman

Tai presented with an emphysematous spleen as a result of torsion. He was intensively managed for presumed septic systemic inflammatory response syndrome (SIRS). A full discussion of management of such a patient would take up much more space than we have here, so only brief, general information is provided! Treatment goals for the septic patient include:


**Locating and eliminating the infection.** The abdominal mass effect helped localise the problem to the abdomen. Abdominal radiographs showed lack of serosal detail. Multiple gas filled radiopacities were seen in the mid-abdomen. An abdominal ultrasound identified this structure as the spleen. Several blood vessels within the spleen without blood flow were identified using colour-flow Doppler imaging. The surgery department removed the spleen - you will find information on surgical management of spleens over the page. Broad spectrum IV antibiotic therapy was started immediately to cover gram positive and negative aerobes and anaerobes. Amoxicillin-clavulanic acid,



metronidazole and enrofloxacin were given in this case. Antibiotic therapy can be modified once the causative organism(s)

are cultured and sensitivity tests are performed.

**Maintaining blood pressure and organ perfusion.** This is important as multiple organ systems are compromised in the septic patient. IV fluid boluses can be given (15-20 mL/kg) until adequate perfusion is obtained, or evidence of volume overload occurs. Monitoring central venous pressure is the best way of assessing volume overload. Colloids may also be given to increase blood pressure - whether these are more beneficial than crystalloid fluids is not currently known. They may reduce the likelihood of pulmonary oedema developing. Vasopressors (e.g. dopamine) can be given if blood pressure is not increased with fluid therapy. Blood transfusions in the anaemic patient help maintain oxygen delivery to tissues. A blood transfusion was given to Tai as well as IV crystalloids. A urinary catheter was placed and urine output monitored. Electrolytes and blood glucose levels were also monitored.



**Inhibiting the deleterious actions of cytokines.** There are no proven treatments in veterinary medicine that accomplish this goal. Many have been trialled in human medicine - therapy with activated protein C is the only treatment that has been

shown to reduce mortality in large human studies. This is available, but extremely expensive. It has not been evaluated in dogs or cats. Other management issues we had with Tai included:

**Hypoxaemia.** This was detected on arterial blood gas analysis. Possible causes for hypoxaemia include low inspired oxygen levels, reduced respiratory effort, ventilation-perfusion mismatch, blood shunting and diffusion impairment. An increased respiratory rate combined with no dramatic changes on thoracic radiographs made us suspicious of pulmonary thromboembolism. Another differential diagnosis would be early acute respiratory distress syndrome (ARDS). Oxygen therapy was provided and treatment with low molecular weight heparin was given to reduce the chance of further thromboembolic episodes.

**Ventricular arrhythmias.** These were detected post-surgery, likely secondary to sepsis and hypoxaemia. After treating Tai's metabolic abnormalities lidocaine boluses were given, followed by a constant rate infusion. In Tai's case this did not abolish the arrhythmias. Fortunately they were not seriously compromising his cardiac output and resolved as he improved.

**Gastric ulceration.** Several days after surgery Tai vomited 'coffee grounds', indicative of upper gastrointestinal bleeding. This was likely to be a result of compromised blood supply to the gastrointestinal tract. Oral sucralfate slurry and an H-2 blocker were given and no further problems were seen.



## Splenectomy: Always Easy? - by Richard Jerram

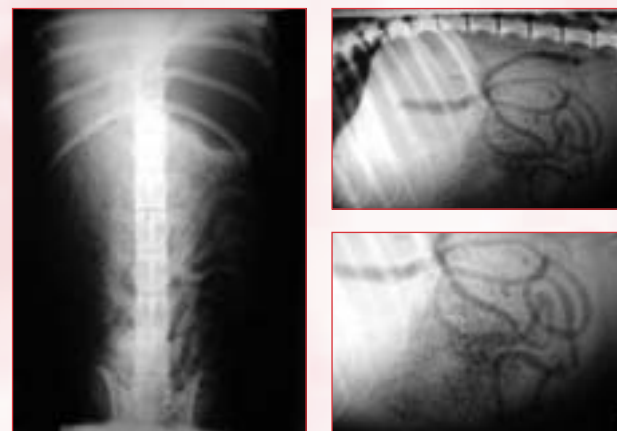
Tai, the dog presented in this newsletter, was a challenging splenectomy case. On entering the abdomen it was apparent that there was an emphysematous splenic torsion that had ruptured prior to surgery. The abdomen was full of fetid, dark fluid limiting visualization of the abdominal contents. Suction of approximately 4 litres of this fluid was required prior to evaluating the remainder of the abdomen. The splenic vessels were tightly torsed and thrombosis of the splenic vein and artery was evident. The splenic pedicle was ligated with large gauge monofilament absorbable suture material (PDS) without untwisting the torsion. Other smaller vessels were ligated with finer suture material or cauterized. The remainder of the abdomen was explored; no other abdominal abnormalities were detected. Prior to closure, the abdominal cavity was extensively lavaged with a total of 5 litres of sterile saline solution with suction performed after each litre was infused. The use of a quality suction unit and electrocautery were essential in helping this procedure be performed rapidly and accurately.

Curiously, splenectomy in dogs was reported as early as the 16th century, goodness knows what their anesthesia protocol was!! It is well recognized that the dog can live without a spleen and splenic surgery is probably the most frequent intra-abdominal procedure encountered in companion animals after routine ovariohysterectomy. The spleen is suspended by the greater omentum and attached to the stomach by the gastrosplenic ligament that contains the short gastric blood vessels. The spleen functions as a reservoir and maintenance organ for red blood cells as well as providing immune and hematopoietic abilities.

Splenectomy is most commonly indicated for mass (neoplasia or hematoma), trauma, and torsion. In most cases, complete splenectomy is recommended; however, occasionally partial splenectomy is indicated. Complete splenectomy can be performed by ligation of the individual hilar vessels or by ligation of the major splenic vessels and the short gastric vessels. The latter technique is quicker and does not compromise blood supply to the stomach wall. Unfortunately, many splenic masses have a large number of omental adhesions making dissection of the larger vessels difficult, necessitating careful ligation of vessels along the splenic hilus.

Some key points regarding splenic surgery:

- Have banked or fresh blood available as intra-abdominal bleeding due to splenic rupture can cause profound anemia.
- Autotransfusion of abdominal blood can be performed if the spleen has had a traumatic rupture.
- Make the laparotomy long enough to be able to exteriorise the spleen comfortably.
- Use laparotomy sponges to isolate the diseased spleen and manipulate the spleen carefully to avoid rupture.
- Surgical suction and a surgical assistant are useful to enable accurate visualization and to make the procedure faster.
- Always double ligate the major splenic vessels (I prefer to isolate the artery and vein separately in large dogs).
- Watch for omental bleeding and ligate if necessary.
- Look out for and avoid the left lobe of the pancreas.
- Always send a section of spleen for histopathology as hematoma and hemangiosarcoma are indistinguishable grossly.
- Don't untwist a splenic torsion as this can release thrombi and vasoactive substances into the general circulation.
- Surgical stapling devices can speed up the surgical time.
- Do a prophylactic gastropexy in dogs predisposed to gastric dilatation-volvulus (GDV).
- Hemorrhage is the most common complication following splenectomy and is generally related to failure of ligatures.
- Cardiac arrhythmias are common postoperatively but generally do not require treatment, however, lidocaine (2mg/kg) should be immediately available.
- Remember that hemangiosarcoma only represents < 24 % of all splenic masses so do not euthanase a dog based on the gross appearance of the spleen.



Lateral & VD radiographs of Tai's abdomen.  
Note the ill-defined structure revealing multiple gas filled radiopacities of various size, giving a honeycomb appearance. Tai's severe weight loss resulted in poor abdominal detail and an impression that the radiograph is over-exposed.

## Staff Focus: - Philippa Wilkinson (Phil)

Phil is part of the veterinary nursing team, working in the surgery department.

**How long have you worked at VSG?**

Four years.

**What do you enjoy about working at VSG?**

I love meeting the pets and their owners. It's great meeting people that feel the same way about animals as we do.

**What do you enjoy doing on the weekends?**

Catching up with my friends and parents and generally just trying to relax and have fun.

**Tell me about your family**

I have an awesome mum & dad, both still working and happy, and an older sister living down in Queenstown.

**What inspired you to become a veterinary nurse?**

I really love animals, all sorts from mice through to elephants, they're just really interesting.

**How many animals do you have at home?**

One cat called Squeak, very ancient but very cool.

**What is your favourite meal?**

Steak with veges and burritos.

**And your favourite TV programme?**


The Simpsons, and sometimes The News, when it's not all bad.

**What is your favourite holiday destination?**

I don't really have one, so maybe Canada. I haven't been there yet but hope to one day.

**If you won Lotto tomorrow, what would you spend the money on?**

I'd like to think I would be sensible and put most of it in the bank, but I don't know.



Philippa Wilkinson



She'd tell you it hurts,  
**if she could.**

The signs of pain can be as subtle and as simple as slowing down. Routine screening identifies problems early on. Treating pain brings dogs back up to speed.

**RIMADYL®**  
SEE THE DIFFERENCE

**Pfizer** Animal Health

A division of Pfizer New Zealand Ltd, Level 3, Pfizer House, 14 Normanby Road, Mt Eden, Auckland. Tel: 0800 650 377, FAX: 0800 628 629 www.pfizer.co.nz Registered pursuant to the ACVM Act 1997. Nos: A7086, A8023, A7084, A7085. P.A.R. Class 1. For use only under the authority or prescription of a veterinarian. Active ingredient: Carprofen. Registered Trademark of Pfizer Ltd.